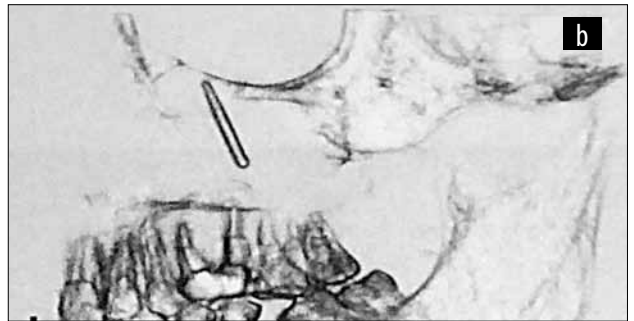
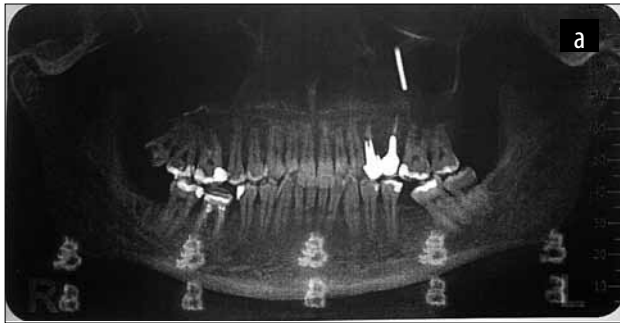


## CLINICAL PHOTOGRAPHS

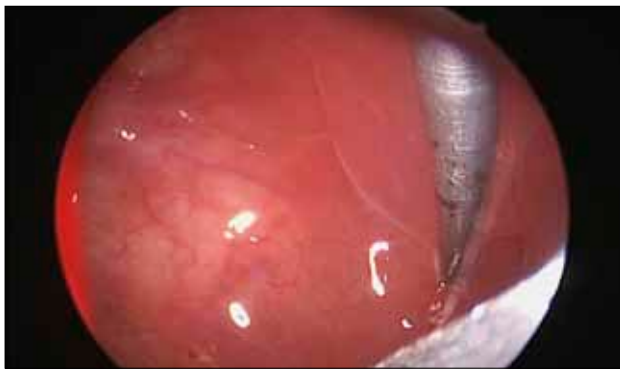# Iatrogenic foreign body of the maxillary sinus – dental burr

Iulia Sabaru, Codrut Sarafoleanu

ENT&HNS Department, “Sfanta Maria” Hospital, Bucharest, Romania



**Figure 1** A. Dental orthopantomography revealing dental burr in the left maxillary sinus. B. 3D perspective of the foreign body



**Figure 2** Left maxillary sinusoscopy: dental burr and thickening of the sinus mucosa



**Figure 3** Dental burr